

Vertebral fusion in two Early Jurassic sauropodomorph dinosaurs from the Lufeng Formation of Yunnan, China

LIDA XING, BRUCE M. ROTHSCHILD, HAO RAN, TETSUTO MIYASHITA,
W. SCOTT PERSONS IV, TORU SEKIYA, JIANPING ZHANG, TAO WANG, and ZHIMING DONG



Xing, L., Rothschild, B.M., Ran, H., Miyashita, T., Scott Persons, W., IV, Sekiya, T., Zhang, J., Wang, T., and Dong, Z. 2015. Vertebral fusion in two Early Jurassic sauropodomorph dinosaurs from the Lufeng Formation of Yunnan, China. *Acta Palaeontologica Polonica* 60 (3): 643–649.

Here we describe two instances of pathological vertebral fusion in two genera of sauropodomorph dinosaurs from the Early Jurassic Lufeng Formation in Yunnan, China. The first is a specimen, of *Lufengosaurus huenei* with two fused cervical vertebrae, and the other is a specimen of the Lufeng basal sauropod, with two fused caudal vertebrae. Both pathologies are consistent with spondyloarthropathy and represent the earliest known occurrence of that disease in dinosaurs. The two specimens affirm that early dinosaurs suffered from the same bone diseases as living vertebrates. Spondyloarthropathy in these dinosaurs may have been induced by long-term mechanical stress, such as weight bearing, and/or limited motion at the joint that would otherwise have inhibited such remodeling. In both cases, surface remodeling suggests that the animals survived well beyond the initiation of spondyloarthropathy.

Key words: Dinosauria, sauropodomorph, spondyloarthropathy, Jurassic, Lufeng Formation, China.

Lida Xing [xinglida@gmail.com] and Jianping Zhang [zhiping@cugb.edu.cn], School of the Earth Sciences and Resources, China University of Geosciences, Beijing 100083, China.

Bruce M. Rothschild [bmr@ku.edu], Division of Vertebrate Paleontology, Natural History Museum and Biodiversity Research Center, University of Kansas, 1345 Jayhawk Boulevard, Lawrence, KS 66045, USA.

Hao Ran [ranhao.cn@gmail.com], Key Laboratory of Ecology of Rare and Endangered Species and Environmental Protection (Guangxi Normal University), Ministry of Education, Guilin 541004, China.

Tetsuto Miyashita [tetsuto@ualberta.ca] and W. Scott Persons IV [persons@ualberta.ca], Department of Biological Sciences, University of Alberta, 11455 Saskatchewan Drive, Edmonton, Alberta T6G 2E9, Canada.

Toru Sekiya [t.sekiya.jlu@gmail.com], Zigong Dinosaur Museum, Zigong 643013, Sichuan, China.

Tao Wang [2625297725@qq.com], Dinosaur Museum of World Dinosaur Valley Park, Lufeng, 651200, China.

Zhiming Dong [lfdinodong@sina.com], Institute of Vertebrate Paleontology and Paleoanthropology, Chinese Academy of Sciences, Beijing 100044, China.

Received 19 June 2013, accepted 3 January 2014, available online 14 January 2014.

Copyright © 2015 L. Xing et al. This is an open-access article distributed under the terms of the Creative Commons Attribution License, which permits unrestricted use, distribution, and reproduction in any medium, provided the original author and source are credited.

Introduction

Vertebral fusion is a serious and common bone disease (Rothschild 1997; Rothschild and Martin 2006) and is widely documented in modern and ancient humans (Rogers et al. 1985; Littleton 1999; Rothschild and Martin 2006), various other mammals (Rothschild and Martin 2006), non-avian dinosaurs (Blumberg and Sokoloff 1961; Rothschild and Ber- man 1991; Rothschild 1997; Molnar 2001; Butler et al. 2013; Farke and O'Connor 2007), reptiles (Rothschild 1997), and fishes (Britz and Johnson 2005). The most obvious causes of vertebral fusion are the ossification of the annulus fibrosus,

often rugose and bulbous bone growth between the joined vertebrae, and the resulting loss of intervertebral flexibility. Depression of the spinal nerve may also result, which may lead to reduced or complete loss of nerve function (Rothschild 1997; Rothschild and Martin 2006; Wu et al. 2008). The pathological vertebral fusion from two genera of sauropodomorph dinosaurs described in this paper are located in Yunnan Province, China.

Institutional abbreviations.—ZLJ, World Dinosaur Valley Park, Lufeng, China.

Other abbreviations.—DISH, diffuse idiopathic skeletal hyperostosis.

Geological setting

The Red Beds of the Lufeng Series in the Lufeng Basin (Fig. 1) are conventionally divided into upper and lower units (Bien 1941). The Lufeng Series was originally described as Late Triassic in age (e.g., Bien 1941; Young 1951). Sheng et al. (1962) proposed an Early Jurassic and Middle Jurassic age for the lower and upper units, respectively. Recent biostratigraphical correlations based on tetrapod and associated invertebrate fossils have supported this Jurassic designation (Sun and Cui 1986; Luo and Wu 1994, 1995). From 1999 to 2000, Fang and colleagues studied the stratigraphic section at Lao Changqing-Da Jianfeng in the Chuanjie Basin and restricted the name “Lufeng Formation” to what previously was the Lower Lufeng Formation and further divided it into Shawan (Dull Purplish Bed) and Zhangjia’ao (Dark Red Bed) members, and this opinion is followed here. Strata that had at various times been encompassed in the Upper Lufeng Formation were broken into the Chuanjie, Laoluocun, Madishan, and Anning formations (Fang et al. 2000).

Beginning in the 1940s, a wealth of dinosaur fossils have been unearthed in the Lufeng Basin, including material from ornithischians (e.g., Irmis and Knoll 2008), theropods (e.g., Hu 1993; Wu et al. 2009), and the sauropodomorphs *Lufengosaurus* (Young 1941, 1951; Barrett et al. 2005), *Yunnanosaurus* (Young 1942; Barrett et al. 2007), *Jingshanosaurus* (Zhang and Yang 1995), *Xixiposaurus* (Sekiya 2010), and an unnamed basal sauropod (= “Yizhousaurus”) (Chatterjee et al. 2010). The dinosaur fauna of the Lufeng Formation is often collectively referred to as the “*Lufengosaurus* fauna” (e.g., Dong 1992).

Material

The two fossil specimens described here were collected from the Dalishu bonebed, Shawan Member of Lufeng Formation, Lufeng County, Yunnan Province, China. ZLJ T001 is an articulated, but incomplete, skeleton of a basal sauropodomorph dinosaur. ZLJ 0033 is a nearly complete and articulated skeleton of a basal sauropod.

Systematic palaeontology

Dinosauria Owen, 1842

Saurischia Seeley, 1887

Sauropodomorpha von Huene, 1932

Prosauropoda von Huene, 1920

Genus *Lufengosaurus* Young, 1941

Type species: Lufengosaurus huenei Young, 1941; Lufeng Basin, China, Early Jurassic.

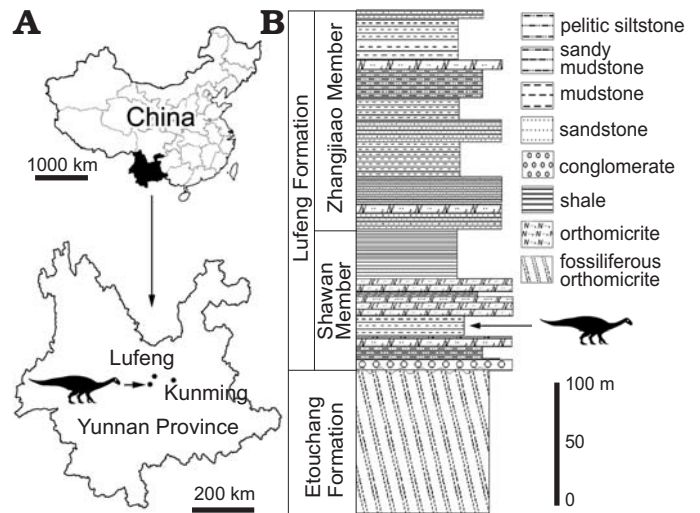


Fig. 1. Location and stratigraphic context of the specimens. **A.** Location (dinosaur silhouette) of the Dalishu bonebed locality in Yunnan Province, China. **B.** Stratigraphic section of Lower Jurassic strata in the Lufeng Basin. Based on Xing et al. (2013).

Lufengosaurus huenei Young, 1941

Fig. 2.

Type material: IVPP V15, a complete skeleton with skull.

Type locality: Shawan Member of Lufeng Formation (Hettangian), Shawan village, Lufeng County, Yunnan Province.

Material.—ZLJ T001 an articulated, but incomplete, skeleton from the Dalishu bonebed, Shawan Member of Lufeng Formation, Lufeng County, Yunnan Province, China. ZLJ T001 and ZLJ 0013 can be referred to *Lufengosaurus huenei* based on the manus longer than the ulna and the pubis-iliac length ratio of 1.1 (Young 1941, 1951; Galton and Upchurch 2004; Barrett et al. 2005).

Description.—ZLJ T001. The posterior cervical vertebrae (6th–10th) of *Lufengosaurus* (Young 1941, 1947) are weakly amphicoelous and lack pleurocoels (Figs. 2–4). The parapophysis develops just below the neurocentral suture to the mid-height of the centrum. There is no bony lamina connecting the parapophysis and the neural arch. The centrum is approximately twice longer anteroposteriorly than tall dorsoventrally, but the height/length ratio gets progressively higher posteriorly within the series. The centrum is constricted ventrally into a gentle hourglass shape in lateral view, and a longitudinal keel develops on the ventral surface between the intervertebral joints. The neural arch is not markedly taller dorsoventrally than the centrum. As a result, the neural spine is a low rectangle in lateral view, anteroposteriorly longer than dorsoventrally tall. The dorsal margin of the neural spine is straight horizontally or slightly posterodorsally inclined. Both pre- and postzygapophysis are robust, round in cross section and projected for less than 20% the length of the centrum beyond the intervertebral joint. The prezygapophysis has a weak ridge along the lateroventral margin in lateral view, whereas the postzygapophysis has a medial wall along all its length below the level of the zygapophyseal articulation.

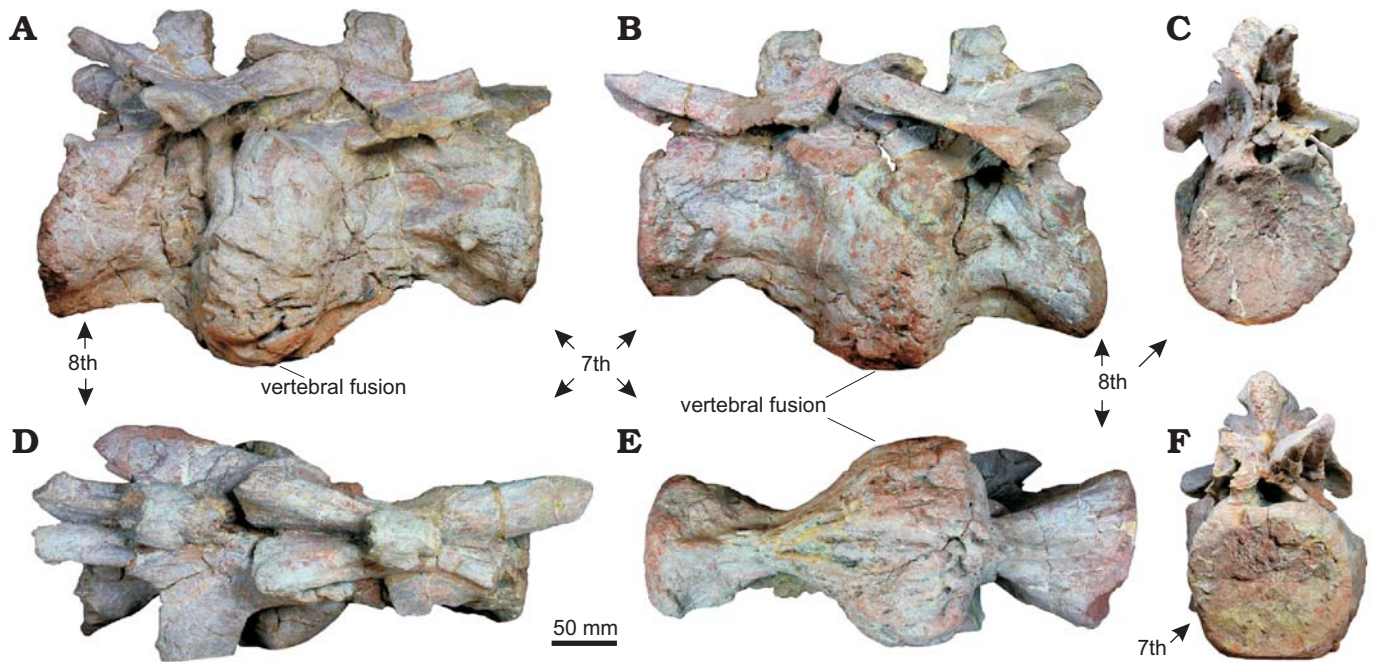


Fig. 2. The 7th and 8th cervical vertebrae of spondyloarthropathy dinosaur *Lufengosaurus huenei* Young, 1941 (ZLJ T001) from Dalishu bonebed, Lower Jurassic, in right lateral (A), left lateral (B), posterior (C), dorsal (D), ventral (E), and anterior (F) views.

The pathologic vertebrae of ZLJ T001 are the 7th and 8th cervical vertebrae (Figs. 2, 3), which are fused at the intervertebral joint (contrast with the normal 7th and 8th cervical vertebrae of *Lufengosaurus huenei* ZLJ 0013; Fig. 4). This region is swollen with anomalous ossification. Like normal posterior cervical vertebrae, the anterior surface of the 7th centrum and the posterior surface of the 8th centrum are both gently concave. A pleurocoel is absent. The ventral keel is present on both centra but splits into two parallel ridges in the pathological region in ventral view. Unlike normal posterior cervical vertebrae, the neural spines are anteroposteriorly shorter than dorsoventrally tall in lateral view. The posterior surface of the neural spines is rugose, with numerous pits and tubercles developed over the normal, smooth texture, which indicates ossification of the interspinous tendons at the site of attachment (Fig. 3).

The 7th cervical vertebra (centrum length: 265 mm; centrum width [anterior]: 125 mm; centrum height [anterior]: 130 mm) has an incompletely closed, visible neurocentral suture. The parapophysis is normal on the right side and poorly preserved on the left. The broken right prezygapophysis shows no abnormal internal structure within that part of the neural arch. The 8th cervical vertebra (centrum length: 190 mm; centrum width [posterior]: 135 mm; centrum height [posterior]: 150 mm) is shorter anteroposteriorly than the 7th cervical vertebra. The parapophysis is just behind the pathological region on both right and left sides.

The centrum fusion between the 7th and 8th cervical vertebrae is due to proliferation and ossification of annulus fibrosus, not by the ossification of the intervertebral ligaments. The surface of the fused region is generally smooth. At the border of the proliferation, some exostoses are visible. No

infection holes or bone density changes are apparent, and the surfaces of each vertebra are free of tooth marks. Inconsistent with infection, the pathology is highly localized and appears only at and around the intervertebral zone, with both the posterior end of the 7th cervical and the posterior end of the 8th cervical having altogether normal appearances.

Stratigraphic and geographic range.—ZLJ T001 and ZLJ 0013 are from Dalishu bonebed, Shawan Member of Lufeng Formation, Lufeng County, Yunnan Province, China.

Dinosauria Owen, 1842

Saurischia Seeley, 1887

Sauropodomorpha von Huene, 1932

Sauropoda Marsh, 1878

Sauropoda gen. et sp. indet.

Fig. 5.

Material.—ZLJ 0033 is a nearly complete and articulated skeleton from the Dalishu bonebed, Shawan Member of Lufeng Formation, Lufeng County, Yunnan Province, China, which was initially identified as *Lufengosaurus huenei* by the World Dinosaur Valley Park. However, subsequent examination by Chatterjee et al. (2010) showed that it is a basal sauropod, but a detailed description has yet to be published. This view is followed here.

Description.—ZLJ 0033 shows fusion between the 4th and 5th caudal vertebrae (Fig. 5). The fusion is due to ossification of the annulus fibrosus, particularly expanded around the lateral margin of the centrum, which makes the region of the intervertebral joint appear swollen. The breakage between the two fused vertebrae reveals that the centra are weakly amphicoe-

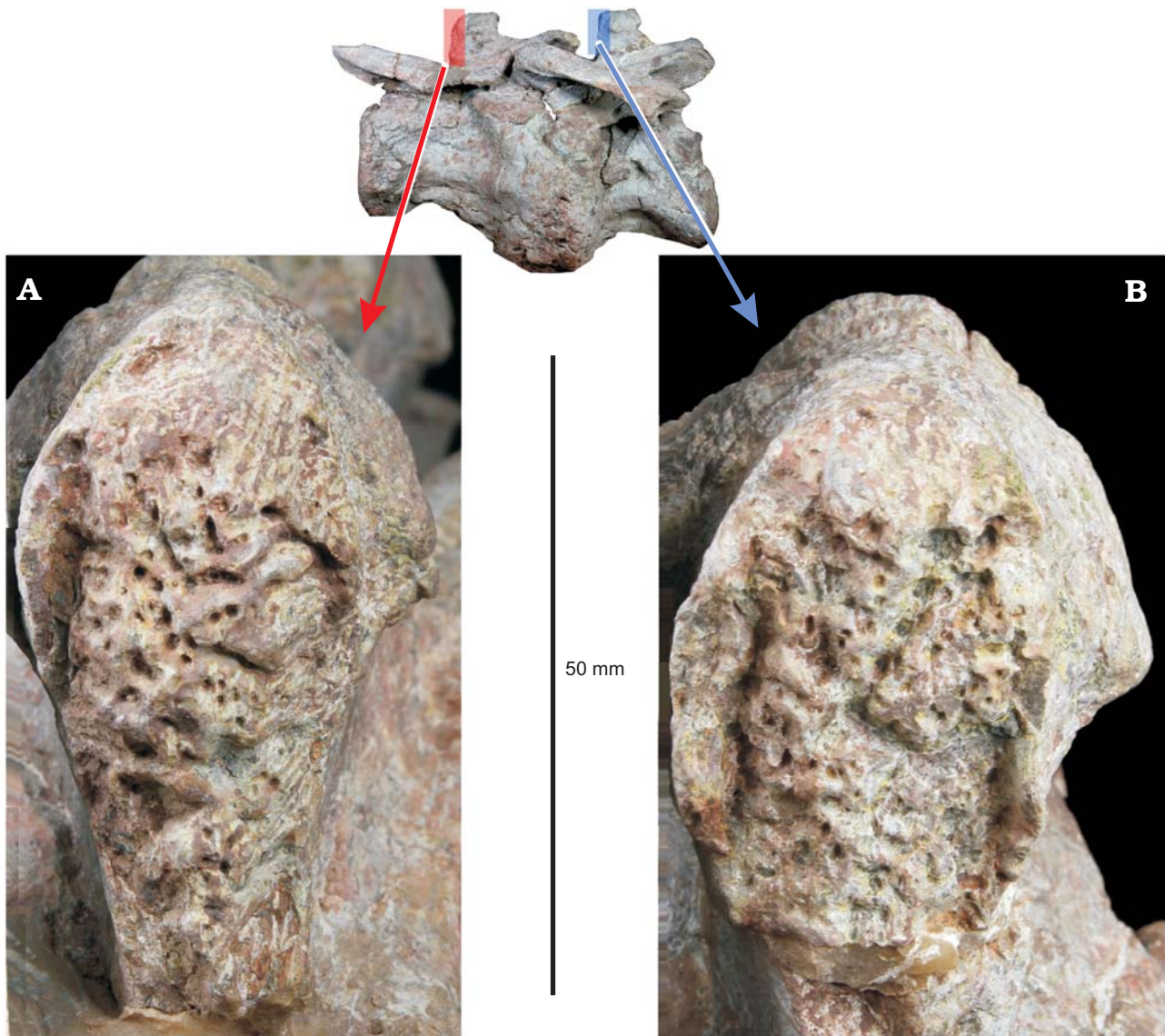


Fig. 3. Details of the rugose surfaces of the posterior neural-spine faces of the 7th (A) and 8th (B) cervical vertebrae of spondyloarthropathy dinosaur *Lufengosaurus huenei* Young, 1941 (ZLJ T001) from Dalishu bonebed, Lower Jurassic.

lous, and the fusion did not affect the intervertebral disc and zygapophyseal contact. As in the pathological cervical vertebrae of ZLJ T001, the surface texture is smooth. At the broken plane, the internal structure and bone density appear identical to those of the other caudal vertebrae. Neither are there tooth marks or any correlates of infection.

Both pathological vertebrae lack pleurocoels and a ventral keel. The 4th caudal vertebra (centrum length: 100 mm; centrum width [anterior]: 110 mm; centrum height [anterior]: 135 mm) is anteroposteriorly shorter than the 5th caudal vertebra (centrum length: 115 mm; centrum width [posterior]: 94 mm; centrum height [posterior]: 125 mm). The neural spine is inclined posterodorsally, and the transverse process extends posterolaterally. The site of attachment for the haemal arch is obliterated by the ossification of the annulus fibrosus between the 4th and 5th caudal vertebrae, but is normal between the 5th and 6th caudal vertebrae.

Discussion

There are several potential causes of pathologic vertebral fusion, including: congenital (as reported in fish by Britz and Johnson [2005]), malformation during the healing of a bone fracture (Lovell 1997; Rothschild 1997; Resnick 2002; Rothschild and Martin 2006; Bulter et al. 2013), infection (Bramlage and Dvm 1998; Rothschild and Martin 2006), diffuse idiopathic skeletal hyperostosis (DISH) (Resnick et al. 1975, 1978; Resnick 2002; Rothschild and Martin 2006; Rothschild 2013), and spondyloarthropathy (Rothschild and Martin 2006).

In both specimens, the fusion is the result of ossification of the annulus fibrosus, not ossification of longitudinal ligaments (Rothschild 1997; Rothschild and Martin 2006). The fused vertebrae are isolated cases, with no other abnormal ossifications detected elsewhere along the axial series or in



Fig. 4. Normal 7th and 8th cervical vertebrae of spondyloarthropathy dinosaur *Lufengosaurus huenei* Young, 1941 (ZLJ 0013) from Lufeng Basin, Lower Jurassic, in left lateral view.

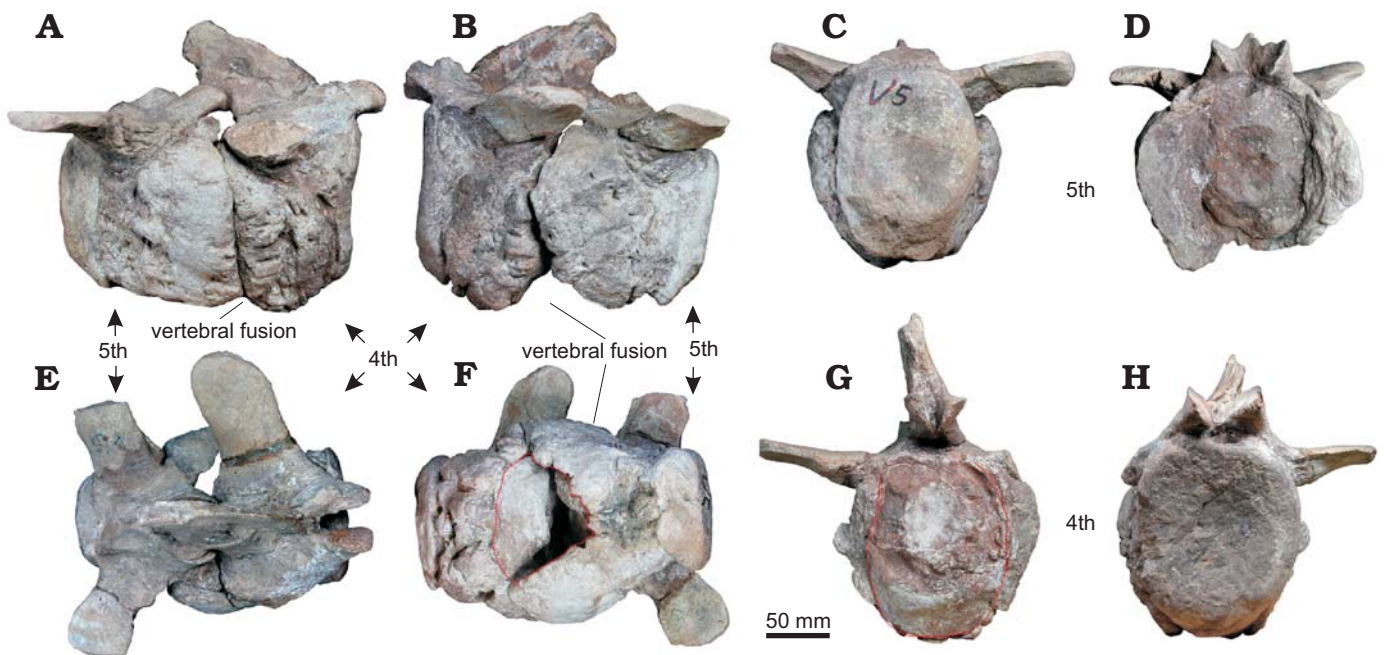


Fig. 5. The 4th and 5th caudal vertebrae of Sauropoda gen. et sp. indet. (ZLJ 0033) from Dalishu bonebed, Lower Jurassic, in right lateral (A), left lateral (B), dorsal (E), and ventral (F) views; anterior (C, G) and posterior (D, H) views of 4th and 5th caudal vertebrae, respectively. Red line in F shows location of the chevron articulation; red line in G shows boundary between proliferation and centrum.

the appendicular skeleton. The external bone surfaces are smooth and there are no scars or fractural vestiges. Thus, injury and healing malformation can be confidently ruled out (Lovell 1997; Rothschild 1997; Resnick 2002; Rothschild and Martin 2006) as can DISH, which is characterized by the fusion of at least three or more vertebrae and by the formation of wave-like bone structure on the ventral side the vertebral column (Resnick et al. 1975, 1978; Resnick 2002; Rothschild

and Martin 2006; Rothschild 2013). No evidence of infection (such as pits or areas of aberrant bone density) was found (Bramlage and Dvm 1998; Rothschild and Martin 2006).

The ossification of the annulus fibrosus, the smooth surfaces of the syndesmophyte, and the obvious proliferation of ossification at the center and along the border of ZLJ T001 and ZLJ 0033 are characteristic of spondyloarthropathy (Rothschild 1997; Rothschild and Martin 2006; Wu et

al. 2008). Distinguishing the various forms of spondyloarthropathy in fossil bones is difficult (Rothschild and Martin 2006). However, the isolated nature of the ossifications rules out ankylosing spondylitis (AS) and inflammatory bowel disease associated arthritis (IBDA), which usually affect numerous vertebrae in a lumbar-cervical progression (Resnick 2002; Stein and Taylor 2004; Rothschild and Martin 2006). As spondyloarthropathy is long-term remodelling of intervertebral joints, these cases of the disorder reported here could have been a response to long-term mechanical stress by weight bearing and/or reduced frequency of motion at joints that would otherwise have prevented such remodelling.

There are reports of spondyloarthropathy in sauropods (e.g., *Camarasaurus*), hadrosaurs, and ceratopsid dinosaurs (Rothschild 1997; Rothschild et al. 2002), but never before in non-sauropod sauropodomorphs. Although there are some examples of spondyloarthropathy in Permian reptiles (Rothschild et al. 2012), the previous earliest record of spondyloarthropathy among dinosaurs comes from *Camarasaurus* (Late Jurassic, late Oxfordian–Tithonian) (Rothschild et al. 2002). These sauropodomorphs (ZLJ T001 and ZLJ 0033) are, therefore, the oldest record of spondyloarthropathy in dinosaurs, being Early Jurassic (Hettangian–Sinemurian).

The two samples are proof that early dinosaurs suffered from bone diseases similar to those afflicting modern vertebrates. The pathologies may have caused dysmorphism of the appearance of the neck and the tail, but, given the limited extent of fusion, the in-life visibility of the pathologies may have been limited. Considering that fusion of even ten vertebrae in humans affected by DISH is not associated with measurable loss of vertebral motion (Rothschild 1982), mobility of the neck and tail may not have been significantly restricted in these individuals. In neither of the sauropodomorphs does the ossification appear to have been life threatening.

In modern large-bodied mammals, vertebral fusions are common. The frequency of spondyloarthropathy is less than 1% in Miocene horses, 2% in Pliocene horses, 3% in Pleistocene horses, and as high as 8% in extant horses. There is a similar progression in rhinoceros from 5% in the Oligocene to 35% today (Rothschild and Martin 2006). Wider and more controlled sampling is required to assess whether these are trends. Taken at face value, however, high levels of the disorder among extant populations of horses and rhinoceros does not appear to be associated with much reduction of fitness.

Fusion of adjacent caudal vertebrae is common among sauropods, especially in *Apatosaurus*, *Camarasaurus*, and *Diplodocus* (Rothschild and Berman 1991). Rothschild and Berman (1991) suggested that the caudal fusion of these sauropods might have been of benefit for a cantilever effect while mating. But the fusion limited to two vertebrae in the series would not have had a measurable effect on such a function. In ceratopsians, the first three cervical vertebrae are fused into a structure known as the syncervical, which may have functioned to support the animals' massive skulls (Rothschild 1997). Though the potential functional benefits of intervertebral fusion remains uncertain, it is clear that, at the expense

of mobility, intervertebral fusion, even that resulting from spondyloarthropathy, would have increased the rigidity of the vertebral column. Nevertheless, intervertebral fusion in the Lufeng sauropodomorph dinosaurs clearly was non-fatal.

Acknowledgements

We thank Laigen Wang (Chairman of World Dinosaur Valley Park, Yunnan Province, Lufeng, China) for providing the dinosaur specimens for study. We thank Paul Barrett (Natural History Museum, London, UK), Phil Mannion (Imperial College London, UK), and Michael Taylor (University of Bristol, UK) for helpful reviews.

References

- Barrett, P.M., Upchurch, P., and Wang, X.L. 2005. Cranial osteology of *Lufengosaurus huenei* Young (Dinosauria: Prosauropoda) from the Lower Jurassic of Yunnan, People's Republic of China. *Journal of Vertebrate Paleontology* 25: 806–822.
- Barrett, P.M., Upchurch, P., Zhou, X.D., and Wang, X.L. 2007. The skull of *Yunnanosaurus huangi* Young, 1942 (Dinosauria: Prosauropoda) from the Lower Lufeng Formation (Lower Jurassic) of Yunnan, China. *Zoological Journal of the Linnean Society* 150: 319–341.
- Bien, M.N. 1941. "Red Beds" of Yunnan. *Bulletin of the Geological Society of China* 21: 159–198.
- Blumberg, B.S. and Sokoloff, L. 1961. Coalescence of caudal vertebrae in the giant dinosaur *Diplodocus*. *Arthritis & Rheumatism* 4: 592–601.
- Bramlage, L.R. and Dvm, M.S. 1998. Infection of bones and joints. *AAEP Proceedings* 44: 148–151.
- Britz, R. and Johnson, G.D. 2005. Occipito-vertebral fusion in ocean sunfishes (Teleostei: Tetraodontiformes: Molidae) and its phylogenetic implications. *Journal of Morphology* 266: 74–79.
- Butler, R.J., Yates, A.M., Rauhut, O.W.M., and Foth, C. 2013. A pathological tail in a basal sauropodomorph dinosaur from South Africa: evidence of traumatic amputation? *Journal of Vertebrate Paleontology* 33: 224–228.
- Chatterjee, S., Wang, T., Pan, S.G., Dong, Z., Wu, X.C., and Upchurch, P. 2010. A complete skeleton of a basal sauropod dinosaur from the early Jurassic of China and the origin of Sauropoda. *Geological Society of America Abstracts with Programs* 42 (5): 26.
- Dong, Z.M. 1992. *Dinosaurian Faunas of China*. 188 pp. China Ocean Press, Beijing.
- Fang, X.S., Pang, Q.J., Lu, L.W., Zhang, Z.X., Pan, S.G., Wang, Y.M., Li, X.K., and Cheng, Z.W. 2000. Lower, Middle, and Upper Jurassic subdivision in the Lufeng region, Yunnan Province. In: *Proceedings of the Third National Stratigraphical Congress of China*, 208–214. Geological Publishing House, Beijing.
- Farke, A.A. and O'Connor, P.M. 2007. Pathology in *Majungasaurus crenatissimus* (Theropoda: Abelisauridae) from the Late Cretaceous of Madagascar. *Journal of Vertebrate Paleontology* 27: 180–184.
- Galton, P.M. and Upchurch, P. 2004. Prosauropoda. In: D.B. Weishampel, P. Dodson, H. Osmólska (eds.), *The Dinosauria, Second Edition*, 232–258. University of California Press, Berkeley.
- Hu, S.J. 1993. A short report on the occurrence of *Dilophosaurus* from Jinning County, Yunnan Province. *Vertebrata Palasiatica* 31: 65–69.
- Huene, F. von 1920. Bemerkungen zur systematic und stammesgeschichte einiger reptilien. *Zeitschrift für Inductiv Abstammungs und Vererbungslehre* 24: 162–166.
- Huene, F. von 1932. Die fossile Reptil-Ordnung Saurischia, ihre Entwicklung und Geschichte. *Monographien Geologie und Paläontologie* 4: 1–361.
- Irmis, R.B. and Knoll, F. 2008. New ornithischian dinosaur material from the Lower Jurassic Lufeng Formation of China. *Neues Jahrbuch für Geologie und Paläontologie, Abhandlungen* 247: 117–128.

- Littleton, J. 1999. Paleopathology of skeletal fluorosis. *American Journal of Physical Anthropology* 109: 465–483.
- Lovell, N.C. 1997. Trauma analysis in paleopathology. *American Journal of Physical Anthropology* 40: 139–170.
- Luo, Z.X. and Wu, X.C. 1994. The small tetrapods of the Lower Lufeng Formation, Yunnan, China. In: N.C. Fraser and H.D. Sues (eds.), *The Shadow of the Dinosaurs: Early Mesozoic Tetrapods*, 251–270. Cambridge University Press, Cambridge.
- Luo, Z.X. and Wu, X.C. 1995. Correlation of vertebrate assemblage of the Lower Lufeng Formation, Yunnan, China. In: A.L. Sun, and Y. Wang (eds.), *Sixth Symposium on Mesozoic Terrestrial Ecosystems and Biotas, Short Papers*, 83–88. China Ocean Press, Beijing.
- Marsh, O.C. 1878. Principal characters of American Jurassic dinosaurs. Part I. *American Journal of Science* 16: 411–416.
- Molnar, R.E. 2001. Theropod paleopathology: a literature survey. In: D.H. Tanke and K. Carpenter (eds.), *Mesozoic Vertebrate Life*, 337–363. Indiana University Press, Bloomington.
- Owen, R. 1842. Report on British Fossil Reptiles. Part II. *Reports of the British Association for the Advancement of Science* 11:60–204.
- Resnick, D. 2002. *Diagnosis of Bone and Joint Disorders* (4th edn). 4944 pp. WB Saunders, Philadelphia.
- Resnick, D., Guerra, J., and Robinson, C.A. 1978. Association of diffuse idiopathic skeletal hyperostosis (DISH) and calcification and ossification of the posterior longitudinal ligament. *American Journal of Roentgenology* 131: 1149–1153.
- Resnick, D., Shaul, S.R., and Robins, J.M. 1975. Diffuse idiopathic skeletal hyperostosis (DISH): Forestier's disease with extraspinal manifestations. *Radiology* 115: 523–524.
- Rogers, J., Watt, I., and Dieppe, P. 1985. Palaeopathology of spinal osteophytosis, vertebral ankylosis, ankylosing spondylitis, and vertebral hyperostosis. *Annals of the Rheumatic Diseases* 44: 113–120.
- Rothschild, B.M. 1982. *Rheumatology: A Primary Care Approach*. 416 pp. Yorke Medical Press, New York.
- Rothschild, B.M. 1997. Dinosaurian paleopathology. In: J.O. Farlow and M.K. Brett-Surman (eds.), *The Complete Dinosaur*, 426–448. Indiana University Press, Bloomington.
- Rothschild, B.M. 2013. Diffuse idiopathic skeletal hyperostosis. *eMedicine Orthopedic Surgery*. <http://emedicine.medscape.com/article/1258514-overview>.
- Rothschild, B.M. and Berman, D.S. 1991. Fusion of caudal vertebrae in late Jurassic sauropods. *Journal of Vertebrate Paleontology* 11: 29–36.
- Rothschild, B.M. and Martin, L.D. 2006. Skeletal impact of disease. *New Mexico Museum of Natural History & Science, Bulletin* 33: 1–226.
- Rothschild, M.B., Helbing, M., and Miles, C. 2002. Spondyloarthropathy in the Jurassic. *The Lancet* 360: 1454.
- Rothschild, B.M., Schultze, H-P., and Pellegrini, R. 2012. *Herpetological Osteopathology: Annotated Bibliography of Amphibians and Reptiles*. 450 pp. Springer, New York.
- Seeley, H.G. 1887. On the classification of the fossil animals commonly called Dinosauria. *Proceedings of the Royal Society of London* 43: 165–171.
- Sekiya, T. 2010. A new prosauropod dinosaur from Lower Jurassic in Lufeng of Yunnan. *Global Geology* 29: 6–15.
- Sheng, S.F., Chang, L.Q., Cai, S.Y., and Xiao, R.W. 1962. The problem of the age and correlation of the red beds and the coal series of Yunnan and Szechuan. *Acta Geologica Sinica* 42: 31–56.
- Stein, C.M. and Taylor, G. 2004. *The Encyclopedia of Arthritis*. 384 pp. Facts On File, New York.
- Sun, A.L. and Cui, K.H. 1986. A brief introduction to the Lower Lufeng saurischian fauna (Lower Jurassic: Lufeng, Yunnan, People's Republic of China). In: K. Padian (ed.), *The Beginning of the Age of Dinosaurs: Faunal Change Across the Triassic–Jurassic Boundary*, 275–278. Cambridge University Press, Cambridge.
- Wu, H.T., Chou, C.T., Chiou, H.J., and Chang, C.Y. 2008. Imaging characteristics of spondyloarthropathy. *Current Rheumatology Reviews* 4: 124–130.
- Wu, X., Currie, P.J., Dong, Z., Pan, S., and Wang, T. 2009. A new theropod dinosaur from the Middle Jurassic of Lufeng, Yunnan, China. *Acta Geologica Sinica* 83: 9–24.
- Xing, L.D., Roberts, E.M., Harris, J.D., Gingras, M.K., Ran, H., Zhang, J.P., Xu, X., Burns, M.E., and Dong, Z.M. 2013. Novel insect traces on a dinosaur skeleton from the Lower Jurassic Lufeng Formation of China. *Palaeogeography, Palaeoclimatology, Palaeoecology* 388: 58–68.
- Young, C.C. 1941. A complete osteology of *Lufengosaurus huenei* Young (gen. et sp. nov.) from Lufeng, Yunnan, China. *Palaeontologica Sinica (Series C)* 7: 1–53.
- Young, C.C. 1942. *Yunnanosaurus huangi* Young (gen. et sp. nov.), a new Prosauropoda from the Red Beds at Lufeng, Yunnan. *Bulletin of the Geological Society of China* 22 (122): 63–104.
- Young, C.C. 1947. On *Lufengosaurus magnus* Young (sp. nov.) and additional finds of *Lufengosaurus huenei* Young. *Palaeontologica Sinica (Series C)* 12: 1–53.
- Young, C.C. 1951. The Lufeng saurischian fauna. *Palaeontologica Sinica (Series C)* 13: 1–96.
- Zhang, Y.H. and Yang, Z.L. 1995. *A New Complete Osteology of Prosauropod in Lufeng Basin Yunnan China: Jingshanosaurus*. 100 pp. Yunnan Publishing House of Science and Technology, Kunming.